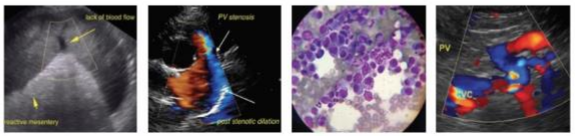



**PATIENT**
Finn Smith

**SPECIES**
Canine

**BREED**
LG

**SEX**
MN

**AGE**
7 years

**WEIGHT**
33 kg

**INTERPRETED BY**
Remo Lobetti, BVSc, MMedVet (Med), PhD, Dipl. ECVIM

**IMAGING PERFORMED BY**
Seth Mitchel, DVM

**HOSPITAL NAME**
Treasure Coast Animal Emergency

**REFERRING VET**

**INVOICE**
303150

**DATE**
7/27/22

## PRESENTING CLINICAL SIGNS

History: N/A.

Physical Examination: N/A.

Urinalysis: N/A

CBC: N/A.

Serum Biochemistry: N/A.

Radiographic Findings: N/A.

## ULTRASONOGRAPHIC EXAMINATION OF THE ABDOMEN

### *Urinary System*

Full urinary bladder with a normal thickness and appearance of the wall. Normal anechoic urine with no sediment or uroliths evident.

Normal trigone area, proximal urethra (0.9 cm), and iliac blood vessels.

Normal iliac lymph nodes. Ureters not visualized.

Normal renal size (left 6.7 cm, right 6.2 cm), echogenic appearance, cortico-medullary differentiation, pelvis, and capsule.

### *Reproductive System*

Small hypoechogenic prostate (1.1 cm).

### *Adrenal Glands*

Normal shape, echogenic appearance, position, and size. Left 0.54 cm, right 0.66 cm.

### *Spleen*

Normal size and echogenic appearance. Smooth homogenous parenchyma, smooth curvilinear capsule, and normal vasculature. No evidence of inflammatory, neoplastic, infarction, or infiltrative changes noted.

### *Liver*

Normal size, echogenic appearance, portal markings, and curvilinear capsule. No nodules or masses evident. Small gall bladder containing normal anechoic bile. Normal thickness and echogenic appearance of the gall bladder wall. Normal bile duct.

### *Gastrointestinal*

Normal appearance of the stomach, duodenum, small intestine, ileo-cecal junction, and colon with no loss of layering, normal wall thickness (jejunum 0.2 cm) and peristaltic activity, and no distension of the lumen.

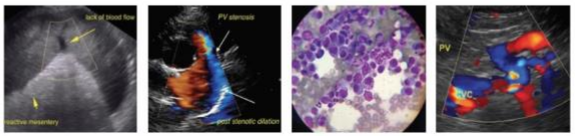



**PATIENT**
Finn Smith

**SPECIES**
Canine

**BREED**
LG

**SEX**
MN

**AGE**
7 years

**WEIGHT**
33 kg

**INTERPRETED BY**
Remo Lobetti, BVSc, MMedVet (Med), PhD, Dipl. ECVIM

**IMAGING PERFORMED BY**
Seth Mitchel, DVM

**HOSPITAL NAME**
Treasure Coast Animal Emergency

**REFERRING VET**

**INVOICE**
303150

**DATE**
7/27/22

### *Pancreas*

Normal size and echogenic appearance. Normal echogenic appearance of the mesentery and fat surrounding the pancreas.

### *Free Abdomen*

Normal mesenteric lymph nodes (0.4 cm).
No ascites.

## ULTRASONOGRAPHIC FINDINGS

Primary findings:

- None.

Secondary findings:

- None.

## INTERPRETATION OF THE FINDINGS & FURTHER RECOMMENDATIONS

Normal ultrasound examination of the abdomen.

**The information and recommendations provided are based on the images presented by the referring veterinarian. No evaluation can be communicated regarding pathology that was not visible in the image/video clips provided.**

Thank you for this referral. If the clinical or image interpretation does not parallel your findings or if I can be of any further assistance please contact me.

**Remo Lobetti,** BVSc, MMedVet (Med), PhD, Dipl. ECVIM (Internal Medicine)
rlobetti@mweb.co.za